

Bullous Pilomatricoma: A Rare Morphological Variant of a Common Adnexal Tumor

1.Dr. Nishkarsh Chugh

Junior Resident

Department of Dermatology, Venereology and Leprosy
Rama Medical College and Hospital, Hapur

2.Dr. Anant Khandelwal

Senior Resident

Department of Dermatology, Venereology and Leprosy
Shri Ram Murti Smarak Institute Of Medical Sciences, Bareilly

3.Dr. Kanika Roy

Assistant Professor

Department of Dermatology, Venereology and Leprosy
Rama Medical College and Hospital, Hapur

4.Dr. Md. Raihan

Professor and Head of Department

Department of Dermatology, Venereology and Leprosy
Rama Medical College and Hospital, Hapur

Corresponding Author: Dr. Nishkarsh Chugh

Junior Resident

Department of Dermatology, Venereology and Leprosy
Rama Medical College and Hospital, Hapur

Abstract: *Pilomatricoma, also known as calcifying epithelioma of Malherbe, is a benign adnexal tumor originating from hair matrix cells. Its bullous or lymphangiectatic variant is an uncommon entity, comprising only 2–6% of all cases.¹ The presence of a pseudobullous component often mimics other bullous or cystic dermatoses, creating diagnostic dilemmas. This article details a case of bullous pilomatricoma in a 17-year-old female and provides an overview of its etiopathogenesis, clinical manifestations, histopathology, imaging, management, and prognosis.*

Keywords:

Pilomatricoma, Bullous Pilomatricoma, Calcifying Epithelioma of Malherbe, Hair Matrix Tumor, Anetoderma

Introduction:

Pilomatricoma is the most common benign adnexal tumor of the hair follicle matrix and is

frequently seen in individuals within the first two decades of life.² It shows a female preponderance and most commonly occurs in the shoulder and upper arm region.³ Despite its common occurrence, the bullous or lymphangiectatic subtype remains extremely rare, accounting for only 2–6% of cases.¹ The bullous morphology arises due to superficial dermal changes⁴, often leading to misdiagnosis as lymphangioma, bullous morphea, or secondary anetoderma. The condition is also referred to as lymphangiectatic pilomatricoma or secondary anetoderma over pilomatricoma. Genetic mutations involving β -catenin⁵ and Bcl-2⁶ play a role in its pathogenesis, and syndromic associations have been observed in conditions such as myotonic dystrophy, Gardner syndrome, Turner syndrome, and Rubinstein–Taybi syndrome.⁷

Case

Report

A 17-year-old female presented with a slow-growing, painless, translucent bullous lesion on the right side of her back (Fig. 1). The lesion began as a small papule and gradually enlarged over six months, eventually developing a gelatinous, flaccid, thick-walled bulla overlying a firm, chalky-white subcutaneous nodule (Fig. 2). Clinical examination demonstrated a “bouncy ball sign,” a characteristic feature described by Belliappa et al⁸. The lesion measured approximately 3 × 2.5 cm and was adherent to the overlying skin without signs of inflammation, trauma, systemic illness, or family history. Ultrasonography revealed a well-demarcated, superficial hypoechoic lesion without deep muscular or osseous involvement. Complete surgical excision was performed (Fig.3), and the specimen was sent for histopathological evaluation. Postoperative recovery was uneventful, and no recurrence was noted over a six-month follow-up period.

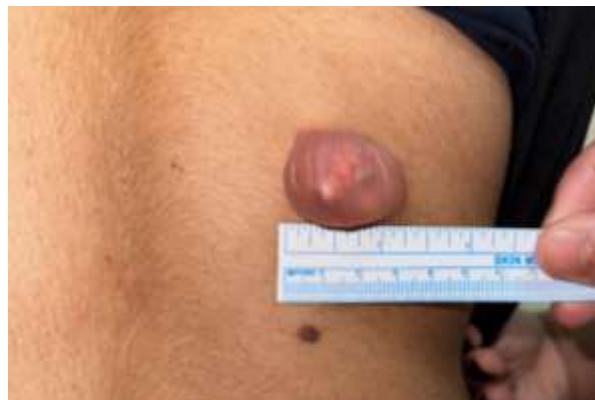

Fig 1. Preoperative photograph showing the thick-walled translucent bulla, sized approximately 3 x 2.5cm overlying a chalky white nodule on the right side of the back of the patient

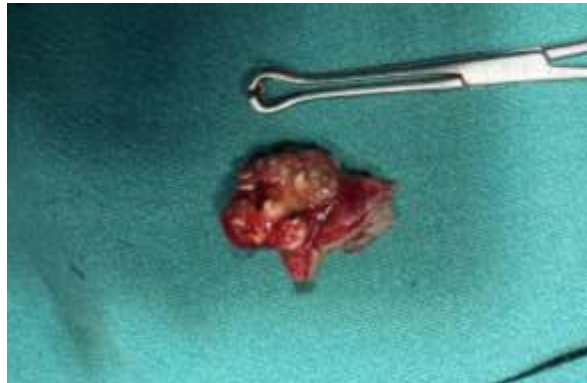

Fig 2. Postoperative macroscopic appearance of the totally excised firm chalky white nodule showing a lobulated appearance

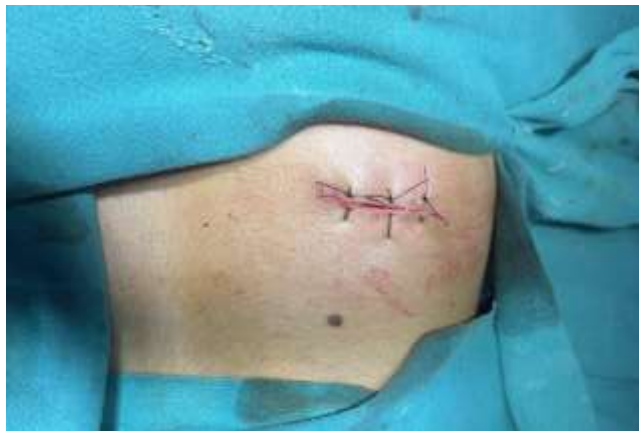

Fig 3. Postoperative macroscopic appearance of right side of patient's back after total excision

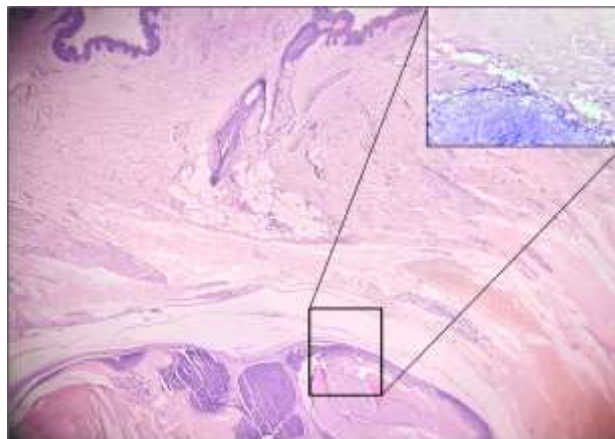


Fig 4. 10x magnification hematoxylin and eosin (H&E) staining histopathology image displaying the plane of bullous split (inset with 40x magnification displaying ghost cells consistent with pilomatricoma)

Discussion:

Pilomatricoma originates from primitive hair matrix cells, leading to abnormal keratinization and calcification in the lower dermis and subcutaneous tissue. In the bullous variant, the tumor exerts pressure on dermal lymphatic vessels, leading to lymphatic obstruction, congestion, and dilation of superficial lymphatics. This results in dermal edema and formation of a pseudobulla.⁴ Matrix metalloproteinases (MMP-9 and MMP-12), released by tumor and inflammatory cells, have been implicated in elastic fiber degeneration, contributing to secondary anetoderma-like changes.^{9, 10, 11}

Clinically, the lesion typically appears as a solitary, firm, well-demarcated subcutaneous nodule measuring 1–3 cm, often chalky-white on cut section. The overlying flaccid bulla appears semitransparent, erythematous or bluish, with a jelly-like consistency.^{3, 4} Signs such as the “bouncy ball sign”⁸, buttonholing seen in anetoderma, or dimpling^{12, 13} may be present.

Histopathologically, pilomatricoma is characterized by well-demarcated lobules composed of ghost or shadow cells displaying eosinophilic cytoplasm and distinct borders without nuclei. (Fig.4) Basaloid cells with oval nuclei and mitotic activity are present at the periphery⁵. Foreign body giant cell reaction, fibrosis, small calcification foci, and a capsule in the deep dermis are observed. The overlying superficial dermis shows dilated lymphatic vessels and dermal edema^{4, 14} with reduced elastic fibers on special staining.^{10, 11}

Immunohistochemically, CD34, D2-40, Ki-67, and p63 positivity have been reported.³ Ultrasonography typically demonstrates an unevenly hypoechoic, non-invasive lesion with blood flow signals, whereas MRI may show a circular soft tissue signal with surrounding high T2 intensity.³

Differential diagnoses include lymphangioma, bullous morphea, dermatofibroma, secondary anetoderma, epidermoid or dermoid cysts, infected sebaceous cysts, and vascular lesions.

Complete surgical excision remains the treatment of choice, as the lesion does not regress spontaneously. Prognosis is excellent, with extremely low recurrence rates and no reported risk of malignant transformation in the bullous subtype.¹⁵

Conclusion

Bullous pilomatricoma is a rare and intriguing variant of pilomatricoma, often overlooked

due to its atypical pseudobullous presentation. Accurate diagnosis requires careful clinical evaluation, supported by imaging and histopathological confirmation. Surgical excision remains curative, offering excellent cosmetic and long-term outcomes.

References

1. Fernandes BF, Al-Hinai A, Belfort RN, Castiglione E, Arthurs B, Burnier MN Jr. Anetodermic variant of a periorbital pilomatricoma. *Ophthalmic Plast Reconstr Surg*. 2008;24(5):419–421.
2. Weichert G, Bush K, Crawford R. Bullous pilomatricoma: report of clinical and pathologic findings and review of dermal bullous disorders. *J Cutan Med Surg*. 2001;5:394–396.
3. Fan YY, Li JF, Su YJ, Jia CY. Pilomatricoma with bullous appearance: a case report. *Int J Dermatol Venereol*. 2023;6(2):118–120.
4. Inui S, Kanda R, Hata S. Pilomatricoma with a bullous appearance. *J Dermatol*. 1997;24:57–59.
5. McCalmont TH. Adnexal neoplasms. In: Bologna JL, Jorizzo JL, Rapini RP, editors. *Dermatology*. 2nd ed. Gurgaon: Mosby; 2009. p. 1698–1699.
6. Chan JJ, Tey HL. Multiple pilomatricomas: case presentation and review of the literature. *Dermatol Online J*. 2010;16(4):2.
7. Kumaran N, Azmy A, Carachi R, Raine PA, Macfarlane JH, Howatson AG. Pilomatrixoma—accuracy of clinical diagnosis. *J Pediatr Surg*. 2006;41:1755–1758.
8. Belliappa P, Umashankar N, Raveendra L. Bullous pilomatricoma: a rare variant resembling bouncy ball. *Int J Trichology*. 2013;5(1):32–34.
9. Motegi SI, Uehara A, Fujiwara C, et al. Pilomatricoma with bullous-like/anetodermic appearance: possibly associated with matrix metalloproteinases. *J Dermatol*. 2018;45(4):505–506.
10. Karadağ AS, Ekşioğlu M, Özlük E, et al. A rare case of pilomatricoma with bullous appearance. *Turk J Med Sci*. 2009;39:333–336.
11. Fetil E, Soyal MC, Menderes A, Lebe B, Güneş AT, Ozkan S. Bullous appearance of pilomatricoma. *Dermatol Surg*. 2003;29:1066–1067.
12. Meffert JJ, Peake MF, Wilde JL. 'Dimpling' is not unique to dermatofibromas. *Dermatology*. 1997;195:384–386.
13. Bhushan P, Hussain SN. Bullous pilomatricoma: a stage in transition to secondary anetoderma? *Indian J Dermatol Venereol Leprol*. 2012;78:484–487.
14. Pirouzmanesh A, Reinisch JF, Gonzalez-Gomez I, Smith EM, Meara JG. Pilomatrixoma: a review of 346 cases. *Plast Reconstr Surg*. 2003;112:1784–1789.
15. Lee SY, Ryu YJ, Her Y, Sung KY. Pilomatricoma: an unusual presentation. *Ann Dermatol*. 2014;26(6):791–792.